

JCO INTERVIEWS

Drs. G. William Arnett and Michael J. Gunson on Esthetic Treatment Planning for Orthognathic Surgery

DR. CHUDASAMA You have noted many sources of cephalometric inadequacy in facial diagnosis and treatment planning. Do you often observe disparities between excellent surgical facial results and osseous cephalometric norms?

DR. ARNETT Diagnosis of malocclusions by cranial-base-derived cephalometric norms such as Steiner, Ricketts, etc., is unreliable. Predominantly, these cephalometric analyses focus measurement on hard tissue. When different cephalometric analyses are used to evaluate the same malocclusion, different diagnoses are indicated. Each analysis provides a different diagnosis, a different

treatment plan, and therefore a different outcome. Treatment based on cephalometric hard-tissue diagnosis may create undesirable facial changes, depending on which analysis is used.

Many possible explanations exist for the inadequacy of cephalometry. The soft tissue covering the teeth and bone can vary so greatly that the dentoskeletal pattern may be inadequate to evaluate facial disharmony. With imbalances in the lip-tissue thickness, facial disharmonies can be observed in the absence of dentoskeletal disharmonies. Another source of cephalometric inadequacy is the cranial base. When the cranial base is used as the reference line to measure the facial



Dr. Arnett



Dr. Gunson



Dr. Chudasama

G. William Arnett, DDS, FACD, and Michael J. Gunson, DDS, MD, are specialists in orthognathic surgery and research in private practice at The Center for Corrective Jaw Surgery, 9 E. Pedregosa St., Santa Barbara, CA 93101; e-mail: arnett@arnettgunson.com and gunson@arnettgunson.com. Dr. Dipak Chudasama is an Assistant Professor and Director of Research, Jacksonville University School of Dentistry, 2800 University Blvd. N., Jacksonville, FL 32211; e-mail: dchudas@ju.edu. A related article by Drs. Arnett and Gunson, "Esthetic Treatment Planning for Orthognathic Surgery", appeared in the March 2010 issue of JCO.

profile, bogus findings can be generated. As an example, are abnormal A point and B point measurements due to A and B projection or to cranial-base abnormality? Measuring a variable (cranial base) to a variable (any dental landmark) gives unreliable information.^{1,2} Michiels and Tourne studied 27 untreated Class I patients to test the validity of various popular cranial-base cephalometric measurements used to predict clinical profiles.³ Their conclusions were: (1) measurements involving cranial-base landmarks are inaccurate in defining the actual clinical profile, (2) measurements involving intrajaw relationships are slightly more accurate in reflecting the true profile, (3) no measurement is 100% accurate, and (4) the variability in soft-tissue thickness and axial inclination of incisors is the greatest source of cranial-base cephalometric inaccuracy.

DR. CHUDASAMA How do the landmarks used for various cephalometric analyses affect diagnostic accuracy?

DR. ARNETT The problem is that each cephalometric study examines different landmarks and measurements as being the key to diagnosis. Therefore, when different cephalometric analyses are used, measuring different structures, the same patient may have different diagnoses and treatment plans. Perhaps cephalometrics are more reliable as a predictor of tissue positions when no skeletal disharmonies are present. Many cephalometric norms have been based on patient populations that had no skeletal disharmonies. When these “normal values” from normal populations are applied to patients with anteroposterior and vertical skeletal disharmonies, they lose validity.

Further problems with cephalometric diagnosis relate to the anatomic areas studied. Complete analysis requires incorporation of vertical and transverse assessments of bite and facial needs. Few orthodontic analyses have used transverse facial analysis because of the reliance on postero-anterior head films for diagnosis and treatment planning. Some look at vertical disparities, whereas others do not.

Still another problem with cephalometric

diagnosis and treatment planning is that the norms may not be accurate because of different soft-tissue posturing. In some studies, the soft tissues were not in a repose position when measurements were made. This is particularly disruptive in the vertical dimension. Vertical skeletal diagnosis depends on assessment of the soft tissues in repose. Closed-lip position may be useful when no skeletal deformity exists, but in the case of skeletal deformity, the closed-lip posture is inaccurate for diagnosis and treatment planning.

DR. CHUDASAMA Is the bilateral sagittal osteotomy (BSO) advancement associated with condylar resorption?

DR. GUNSON Condylar resorption is a late complication of the TMJ associated with orthognathic surgery of either jaw.^{4,5} If the resorption is significant, the distance from condylion to the mandibular incisors shortens, resulting in a Class II dental relationship. Compression of the condyles, no matter the cause, is the most common cause of resorption and relapse. Compression of the mandibular condyle stimulates direct resorptive remodeling at the site of loading because of local tissue disruption and impaired cellular functions. Direct, localized resorption, however, may become global osteolysis of the condyle if a patient has systemic factors such as rheumatoid arthritis, decreased estrogen levels, or low vitamin D levels, to name a few. The resulting resorption with these added systemic factors is severe, usually resulting in a significant anterior open bite and a skeletal Class II relationship (Fig. 1).

Multiple studies have assessed the osseous changes associated with condylar compression.^{4,7,8} These studies have shown consistent osseous resorption of the postglenoid spine and posterior condylar surface when the condyle is posteriorized and compressed in the glenoid fossa. Similarly, Arnett and Tamborello have shown morphologic changes of the mandibular condyle associated with posteriorization and medial or lateral torquing during orthognathic surgery.⁹ The tissue response to compression depends largely on systemic factors. While one individual may exhibit signs and

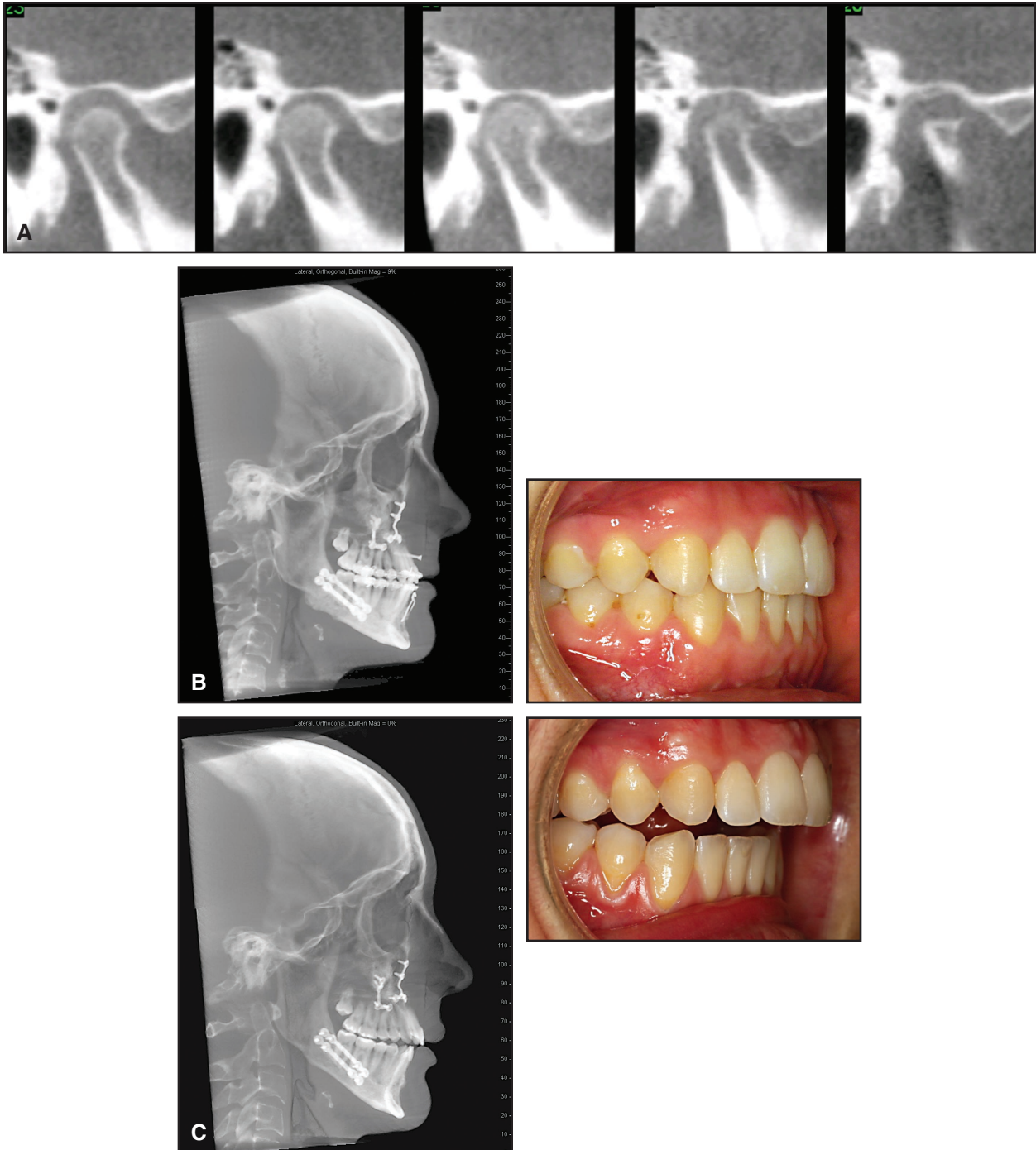


Fig. 1 A. Sagittal slices from successive cone-beam scans of 21 year-old female patient, showing significant condylar resorption after surgery. Far left tomograms were taken before surgery; far right, two years after surgery. Extensive postsurgical history and physical and laboratory examinations were required to identify systemic factors that might have contributed to gross condylar resorption. Kallman's syndrome (no ovarian estrogen production⁶) was revealed. B. Seven months after surgery, showing proper overbite and overjet. C. Two years after surgery, showing effects of gross condylar resorption: steep mandibular plane, early posterior contact, increased overjet, anterior open bite, and Class II malocclusion.

symptoms of aggressive dysfunctional remodeling, such as condylolysis, another individual sustaining a similar condylar insult during surgery might adapt to the changes in mechanical stress and manifest only local, functional remodeling of the condyle.

DR. CHUDASAMA What effect does the surgical procedure have on the condyles?

DR. GUNSON The surgeon influences the position of the condyle by two factors: the direction of force applied to the condyle and the magnitude of force applied. Condyles placed with different vectors of force assume different positions in the glenoid fossa. The condyle does not seat in the preoperative position just because it is pushed toward the fossa.

In addition, the type of hardware and how it is applied to immobilize the osteotomies can have a large influence on the final condylar position in all three planes of space. Condylar compression results from changing the preoperative condylar position to a new position, usually more posterior and/or superior. In response to compression, remodeling of the joint structures will occur. If compression-related remodeling occurs in the presence of systemic factors, the remodeling is diffuse and results in a posterior, inferior B point and incisor retrusion during the postoperative period.

Medial or lateral compression can also cause TMJ remodeling and late B point and incisor relapse. This occurs when the tooth-bearing fragment is advanced and a first contact point develops between the condyle-bearing and tooth-bearing fragments. If clamping and/or bicortical screws close the gap between the segments, condylar torquing occurs. As the gap is closed, rotation occurs at the first contact point, and the condyle torques to the medial or lateral aspect of the fossa, creating compression. Condylar torque is frequently associated with clamp stabilization of the proximal and distal fragments followed by bicortical screws. By avoiding osteotomy gap closure, potential condylar torquing can be minimized. Hardware should be placed passively, maintaining

the condyle in its properly seated position. If the hardware is not neutral and produces an undesirable condylar position, the disc-condyle morphology and position will be altered and result in postoperative joint complications and/or relapse.

DR. CHUDASAMA Do you believe Le Fort I surgery, which changes the condyle position, can lead to condylar resorption?

DR. ARNETT As with the sagittal osteotomy, Le Fort I surgery is capable of causing condylar compression. Again, systemic factors affect the response of the condyles to the surgical compression. In the case of Le Fort I procedures, pressing the chin posteriorly to seat the condyles positions them in a posterior and inferior position in the glenoid fossae.⁴ Further, any fixation hardware directed posteriorly to obtain condylar seating produces posteriorization of the condyle as well. Stabilization hardware for the maxilla should be placed passively to avoid displacement and compression of the condylar position in the glenoid fossa. The most physiologic joint position is achieved by bivector seating of the condyles while the Le Fort I fixation hardware is placed.⁴ Bivector seating is achieved by standing at the head of the patient, pressing down on the chin with the thumbs, and pressing up on the angles with the fingers (Fig. 2A). The resulting forces seat the condyles anteriorly and superiorly into the glenoid fossa, thus avoiding posterior compression of the condyles.

DR. CHUDASAMA Dr. Arnett, you published a very interesting paper concerning BSO relapse.⁵ What causes relapse, and how do you place the condyle into the glenoid fossa during surgery to prevent it?

DR. ARNETT Relapse can occur at only two anatomic locations after BSO advancement: the osteotomy site (through slippage) and the TMJ. Osteotomy slippage is any decrease in length from condylion to the mandibular incisors that occurs at the BSO surgical site before bony union. Osteotomy slippage occurs before osteotomy union in response to stretching of the paramandibular connective tis-

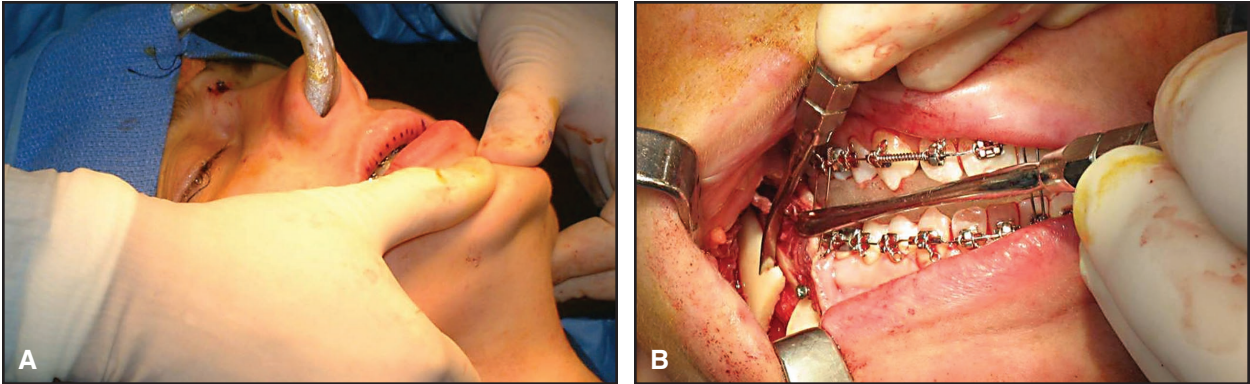


Fig. 2 A. Bivector seating avoids tendency of Le Fort I osteotomy to seat condyle posteriorly and inferiorly in fossa. Extraoral pressure is placed down on chin and up on mandibular angles; resulting vector seats condyle superiorly in fossa. **B.** During surgery, instrument is placed into notch at anterosuperior corner of proximal fragment, with force directed inferiorly. Simultaneously, superior digital pressure is applied extraorally at mandibular angle. Force combination provides superior seating of joint and prevents posterior compression while controlling torque. During bivector seating of condyle, titanium plates are passively adapted and secured across osteotomy gap.

sue (PMCT)—the skin, subcutaneous tissue, muscle, and periosteum—which produces a force pulling the tooth-bearing fragment posteriorly after advancement. Counteracting the PMCT vector is the hardware used to attach the condyle-bearing fragment to the tooth-bearing fragment. If the hardware is ineffective, the mandible shortens across the osteotomy, and early B point relapse occurs. As reported in many studies, wire fixation of the osteotomy is associated with early relapse (osteotomy slippage), and rigid fixation with bicortical screws, or plates with unicortical screws, is associated with early stability (little to no osteotomy slippage).

Condylar compression with morphologic changes, as Dr. Gunson described, accounts for late relapse. When compression occurs, condylar resorption can occur over the long term. As resorption progresses, B point and the teeth relapse at the same time. Bivector seating has been shown to avoid posteriorization of the condyles and to lessen the condylar remodeling seen with other posterior-directed seating techniques.² Bivector condylar seating, instituted by the primary surgeon, places the condyles into the correct anteroposterior position in the glenoid fossae (Fig. 2B).

The second surgeon then places a plate with unicortical screws across the osteotomy gap, which eliminates condylar torquing. The plate is bent to passively contact the lateral surface of the mandible, so that when the screws are tightened, the plates do not change the condyle position mediolaterally or anteroposteriorly.

DR. CHUDASAMA Do you use intraoperative splints to find the correct occlusion during orthognathic surgery?

DR. GUNSON Two splint types are used with orthognathic surgery—intermediate and final. We use intermediate splints during double-jaw surgery to orient the mobilized mandible to the unoperated maxilla. The intermediate splint is made before surgery on a semiadjustable SAM articulator,* using the Great Lakes** model block to assure movement accuracy within .25mm. The model block is used because standard measurements, whether made directly on the casts or on the

*Registered trademark of SAM Präzisionstechnik GmbH, Fussbergstr. 1, D-82131 Gauting bei München, Germany; www.sam-dental.de.

**Great Lakes Orthodontics, Ltd., 200 Cooper Ave., Tonawanda, NY 14150; www.greatlakesortho.com.

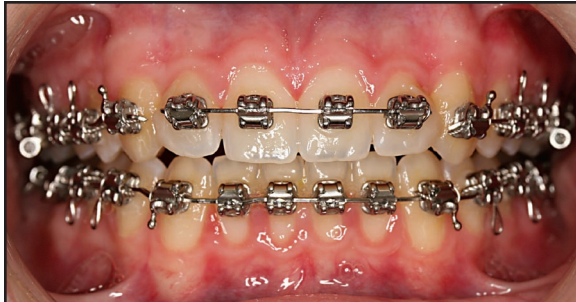

Fig. 3 Maxillary archwire cut three months before surgery, allowing presurgical orthodontic relapse of changes in archform, arch width, and curve of Spee.

articulator, are grossly inaccurate (mean 2.5mm).

We do not use final splints. Our experience has shown that bite correction is not as accurate if a final splint is used. There are 13 steps in making a final splint, all of which can produce error in the final occlusion. Having tooth-to-tooth contact immediately after surgery also results in a more stable and intercuspatated occlusion. Most significant, transverse surgical expansion is less stable when a final splint is used.

DR. CHUDASAMA What are your thoughts regarding the stability of open-bite surgery?

DR. ARNETT Surgical open-bite closure stability is controversial. Denison and colleagues published a paper in which 43% of their 28 patients undergoing surgical closure of open bite had recurrence of the open bite; 22% of the patients actually had no incisor overlap at the longest-term follow-up. They concluded that persistent etiologic factors caused recurrence of the open bite.¹⁰ We have done a similar study at UCLA in which we matched our patient numbers and length of follow-up with the Denison patient group.¹¹ In our study, no patient had open-bite relapse at final follow-up. The basic difference between the Denison group and our group was the type of orthodontic surgical preparation. The Denison group used continuous-archwire surgical preparation to match the upper and lower arch widths, archforms, and planes of occlusion. These ortho-

dontic changes are not stable and cause open-bite relapse after surgery. In our patient group, the orthodontic preparation was done with segmental archwires (Fig. 3). Multisegment Le Fort I surgery was then used to match archform, arch width, and plane of occlusion and to close the open bite. These changes, when achieved with proper surgical techniques, are stable and prevent recurrence of open bite. Haymond and colleagues reported similar surgical open-bite stability related to orthodontic preparation technique.¹²

Aside from orthodontic preparation, several surgical factors are important in assuring stability of open-bite closure. Segmenting between the bicuspid and canine or canine and lateral allows overcorrection of the anterior overbite, unlike one-piece or two-piece Le Fort I surgery. Care should be taken to avoid dental extrusion when intermaxillary fixation is achieved during surgery. Condylar sag, as described by Arnett and Tamborello,⁹ should be avoided. Postoperative anterior skeletal traction with elastics that connect between a midline maxillary bone screw and a midline mandibular wire or bone screw assures overbite stability postoperatively. Finally, to assure long-term open-bite closure, condylar resorption must be avoided. This involves both systemic and compressive factors; the most common source of compression is intraoperative posteriorization or torque of the condyles.

DR. CHUDASAMA What about the stability of surgical expansion?

DR. ARNETT Surgical expansion stability is the most difficult aspect of orthognathic surgery. Phillips and colleagues studied transverse stability after multisegment Le Fort I surgery; in all, 30% of the cases involving first bicuspid expansion and 50% of those involving second molar expansion relapsed.¹³ Seventy-one percent of the patients had no crossbites in spite of transverse relapse. We believe that our transverse stability is much better than that reported by Phillips because our orthodontic preparation and surgical techniques differ from those of the Phillips group. In our patients, we use three- and four-piece Le Fort I designs, two

paramidline osteotomies (Fig. 4), presurgical equilibration, plate fixation, maximal osteotomy bone contact and overlap, and no final splints.

DR. GUNSON Multiple factors determine the stability of maxillary transverse expansion, defined as the sum of orthodontic and surgical relapse. The orthodontic archform, arch width, and plane of occlusion tend to relapse after surgery, contributing to total transverse relapse. To eliminate orthodontic relapse, segmental orthodontic preparation should be used. Maximizing intercuspation is very important to transverse stability. Orthodontically, intercuspation is increased by leveling the marginal ridges and removing posterior rotations. Surgically, intercuspation is maximized by equilibration of the dentition, by using multisegment surgery, and by avoiding final splints. Other surgical factors include using two paramidline nasal-floor osteotomies, which reduces transverse soft-tissue tension; fully mobilizing the segment parts, thus maximizing bone contact and overlap at the horizontal osteotomy; using plate rather than wire fixation; and using appropriate postoperative transverse support. Postsurgical arch support depends on maximal intercuspation, plate fixation at surgery, cross-arch elastics, acrylic support at cut archwire locations, and avoidance of final splints. Final splints prevent full intercuspation and therefore produce transverse relapse, especially when posterior vertical elastics are used.

DR. CHUDASAMA Is two-jaw surgery effective in preventing relapse, especially in cases of anterior open bite?

DR. ARNETT If good orthodontic preparation and stable surgical techniques are used, bimaxillary surgery is stable. The question is not one vs. two jaws; the question is what orthodontic and surgical techniques are used.

DR. CHUDASAMA Do you believe skeletal distraction can replace some orthognathic surgeries?

DR. GUNSON Distraction osteogenesis, in our opinion, will not substitute for conventional ortho-

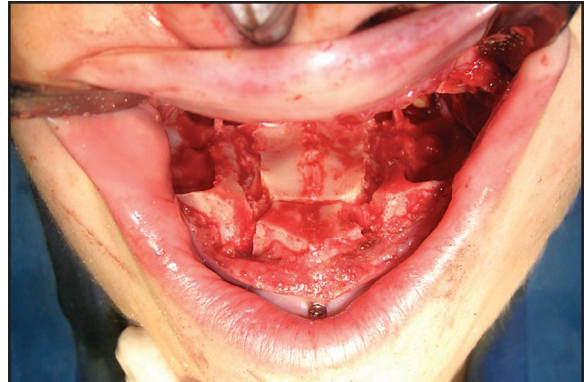

Fig. 4 Two paramidline osteotomies allow greater expansion than single midline osteotomy, as seen in multisegment Le Fort I surgery. In “H” osteotomy, sides of H are paramidline, starting at posterior hard palate and ending between canines and lateral incisors; cross of H is 2cm posterior to anterior nasal spine.

gnathic surgery. Well-done orthognathic surgery with rigid fixation produces occlusal, facial, and airway results that are the gold standard. Distraction osteogenesis does not, and will not, treat the bite in three planes of space with the same quality and precision as conventional, well-done orthognathic surgery. When thinking of distraction, we must realize its limitations. Establishment of precise vectors for distraction is exceedingly difficult. Moving a complex object such as the mandible to within 1mm of accuracy is a veritable impossibility with distraction. There are also severe limits on achieving final occlusion compared with traditional orthognathic surgery. What are the valid clinical reasons to avoid the Le Fort I and sagittal osteotomies in favor of distraction? Previously held beliefs that distraction was kinder to nerve and joint tissues have been proved false. We must be careful not to lower our standards for the sake of using new technology.

Distraction does have clinical relevance when trying to correct large deformities in skeletally immature patients. Treacher-Collins patients often require early intervention to improve airway patency, and distraction can provide this. Severe hemifacial microsomia patients might also require distraction to increase the skeletal mass and struc-

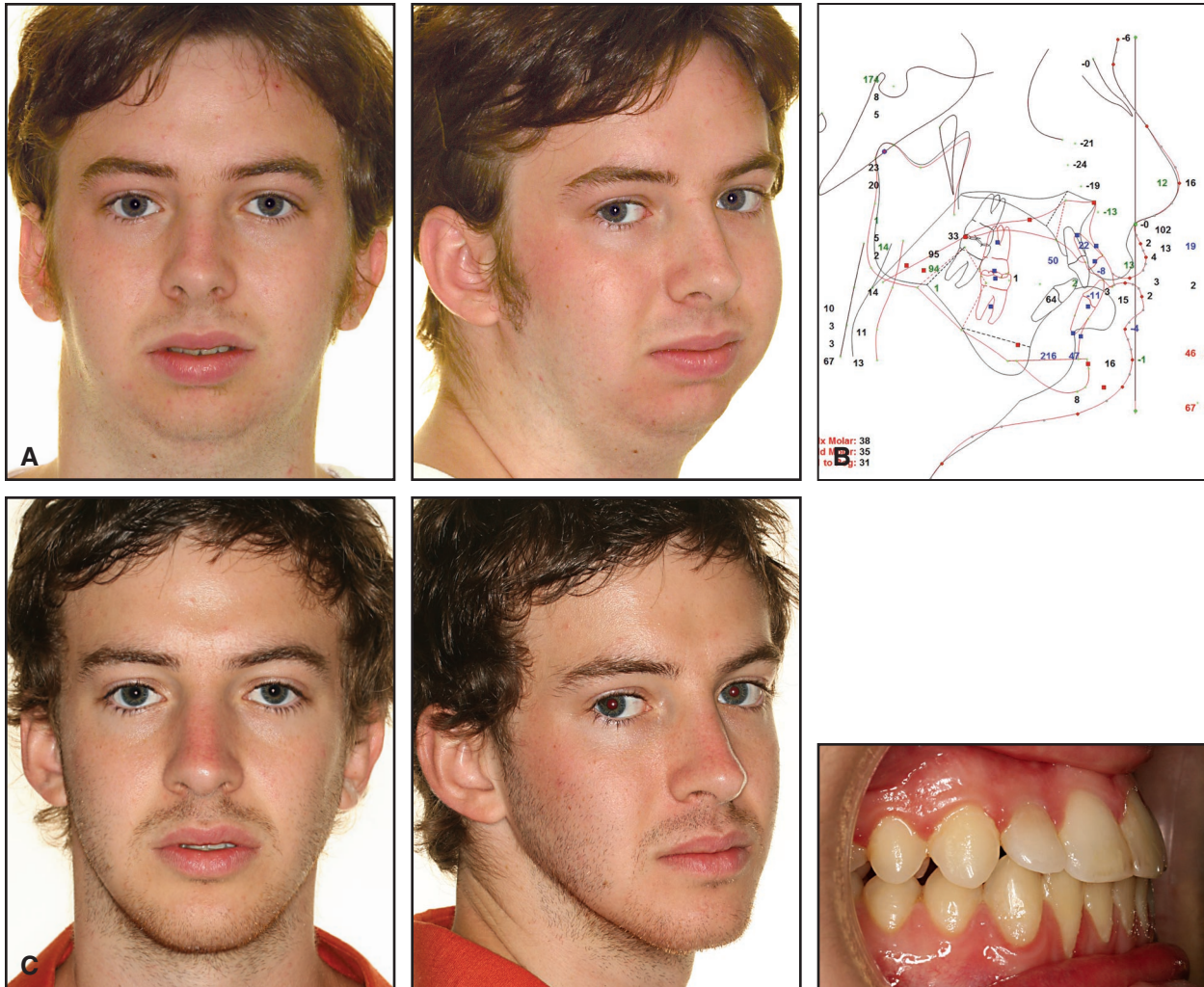


Fig. 5 A. 21-year-old male patient with rheumatoid arthritis, showing lack of mandibular projection, width, and definition. Joint disease was controlled with condyle-sparing medications, including Enbrel*** tumor necrosis factor alpha inhibitor. B. Seven-step cephalometric treatment plan (CTP), showing surgical movements needed to correct face, airway, and bite (FAB). Significant bimaxillary counterclockwise advancements were required: ANS, 0mm; maxillary incisor tip, 9.5mm; mandibular incisor tip, 9.4mm; pogonion, 23.6mm. C. Three and a half years after bimaxillary counterclockwise advancement surgery, note definition of mandibular position in all planes of space. Occlusion was intentionally left Class III at surgery as overcorrection. On Enbrel and other medications, occlusion has remained stable.

ture in the condyle and ramus areas so that future orthognathic surgery can be successful.

DR. CHUDASAMA How do you see the future of orthognathic surgery?

DR. ARNETT Currently, on average, orthodontic and surgical bite-correction results are poor. The probable number-one cause is our training—we focus on the occlusion, with myopia regarding our treatment mission. Many orthognathic surgeons and orthodontists focus treatment exclusively on occlusal correction, many times at the expense of other, equally important factors. To improve our potential, we must define our mission beyond the exclusivity of occlusal correction, to include facial esthetics and airway expansion. Until we define and practice the full scope of treatment, we will continue on the path to mediocrity.

The scope of occlusal correction can be defined as a mission statement or set of goals that should guide bite correction. As the occlusion is corrected, other factors must be maintained if adequate, or even improved if inadequate. These factors include facial appearance, periodontal health, TMJ function, stability, airway expansion, and fulfilling the patient's wishes.¹⁴⁻¹⁷ Unfortunately, when we treat the bite in isolation, the other factors may not improve, but actually worsen. When treatment does not exclusively focus on overjet correction, but instead focuses on the patient as a whole, our treatment can and will become, on average, very good. The future of bite correction (orthodontics and orthognathic surgery), to a large extent, will depend on one thing: our ability to teach goal-oriented treatment (Fig. 5).

ACKNOWLEDGMENTS: The authors thank Dr. Richard P. McLaughlin for his assistance with preparation of this material.

***Registered trademark of Amgen, Inc., One Amgen Center Drive, Thousand Oaks, CA 91320, and Wyeth Pharmaceuticals Inc., 500 Arcola Road, Collegeville, PA 19426; www.enbrel.com.

REFERENCES

1. Arnett, G.W. and Bergman, R.T.: Facial keys to orthodontic diagnosis and treatment planning—Part I, *Am. J. Orthod.* 103:299-312, 1993.
2. Arnett, G.W. and Bergman, R.T.: Facial keys to orthodontic diagnosis and treatment planning—Part II, *Am. J. Orthod.* 103:395-411, 1993.
3. Michiels, L.Y.F. and Tourne, L.P.M.: Nasion true vertical: A proposed method for testing the clinical validity of cephalometric measurements applied to a new cephalometric reference line, *Int. J. Adult Orthod. Orthog. Surg.* 5:43-52, 1990.
4. Arnett, G.W.; Tamborello, J.A.; and Rathbone, J.A.: Temporomandibular joint ramifications of orthognathic surgery, in *Modern Practice in Orthognathic and Reconstructive Surgery*, ed. W.H. Bell, W.B. Saunders Co., Philadelphia, 1992, pp. 523-593.
5. Arnett, G.W.: A redefinition of bilateral sagittal osteotomy (BSO) advancement relapse, *Am. J. Orthod.* 104:506-515, 1993.
6. Gunson, M.J.; Arnett, G.W.; Formby, B.; Falzone, C.; Mathur, R.; and Alexander, C.: Oral contraceptive pill use and abnormal menstrual cycles in women with severe condylar resorption: A case for low serum 17beta-estradiol as a major factor in progressive condylar resorption, *Am. J. Orthod.* 136:772-779, 2009.
7. Arnett, G.W.; Milam, S.B.; and Gottesman, L.: Progressive mandibular retrusion—idiopathic condylar resorption—Part 1, *Am. J. Orthod.* 110:8-15, 1996.
8. Arnett, G.W.; Milam, S.B.; and Gottesman L.: Progressive mandibular retrusion—idiopathic condylar resorption—Part 2, *Am. J. Orthod.* 110:117-127, 1996.
9. Arnett, G.W. and Tamborello, J.A.: Progressive class II development—female idiopathic condylar resorption, *Oral Maxillofac. Surg. Clin. N. Am.* 2:699-716, 1990.
10. Denison, T.F.; Kokich, V.G.; and Shapiro, P.A.: Stability of maxillary surgery in openbite versus nonopenbite malocclusions, *Angle Orthod.* 59:5-10, 1989.
11. Arnett, G.W. and Gunson, M.J.: Unpublished data, 2009.
12. Haymond, C.S.; Stoelinga, P.J.; Blijdorp, P.A.; Leenen, R.J.; and Merckens, N.M.: Surgical orthodontic treatment of anterior skeletal open bite using small plate internal fixation. One to five year follow-up, *Int. J. Oral Maxillofac. Surg.* 20:223-227, 1991.
13. Phillips, C.; Medland, W.H.; Fields, H.W. Jr.; Proffit, W.R.; and White, R.P. Jr.: Stability of surgical maxillary expansion, *Int. J. Adult Orthod. Orthog. Surg.* 7:139-146, 1992.
14. Arnett, G.W.; Gunson, M.J.; and McLaughlin, R.P.: Three-dimensional facial treatment planning, in *Distraction Osteogenesis of the Facial Skeleton*, ed. W.H. Bell and C.A. Guerrero, B.C. Decker, Hamilton, Ontario, 2007, pp. 1-10.
15. Arnett, G.W. and Gunson, M.J.: Facial planning for orthodontists and oral surgeons, *Am. J. Orthod.* 126:290-295, 2004.
16. Arnett, G.W. and Gunson, M.J.: Facial analysis: The key to successful dental treatment planning, *J. Cosmet. Dent.* 21:20-33, 2005.
17. Arnett, G.W.; Jelic, J.S.; Kim, J.; Cummings, D.R.; Beress, A.; Worley, C.M. Jr.; Chung, B.; and Bergman, R.: Soft tissue cephalometric analysis: Diagnosis and treatment planning of dentofacial deformity, *Am. J. Orthod.* 116:239-253, 1999.